



# Small Group Discussion

#1

Presented By:  
Dr. Ranbir Singh  
Dr. Sakshi Sharma



# The patient

- A 5 year old boy presents to the pediatric dental clinic upon referral from pediatrician regarding multiple carious lesions.





# Question #1

- How would you proceed? (ie: What would you ask? What else would you want to know?)



## Question #2

- Mother states that the patient does not complain of any pain, but she does not like the color of his front teeth. Given this information, how would you proceed?





# Additional Information

- Your assistant comes back with the following information. The patient weighs 46 lbs, is 45 inches tall. You calculate the BMI as 17.5 for this patient's age, which is at the 92<sup>nd</sup> percentile. The patient seems cooperative enough to interact with you and your staff, but does so with some reticence.

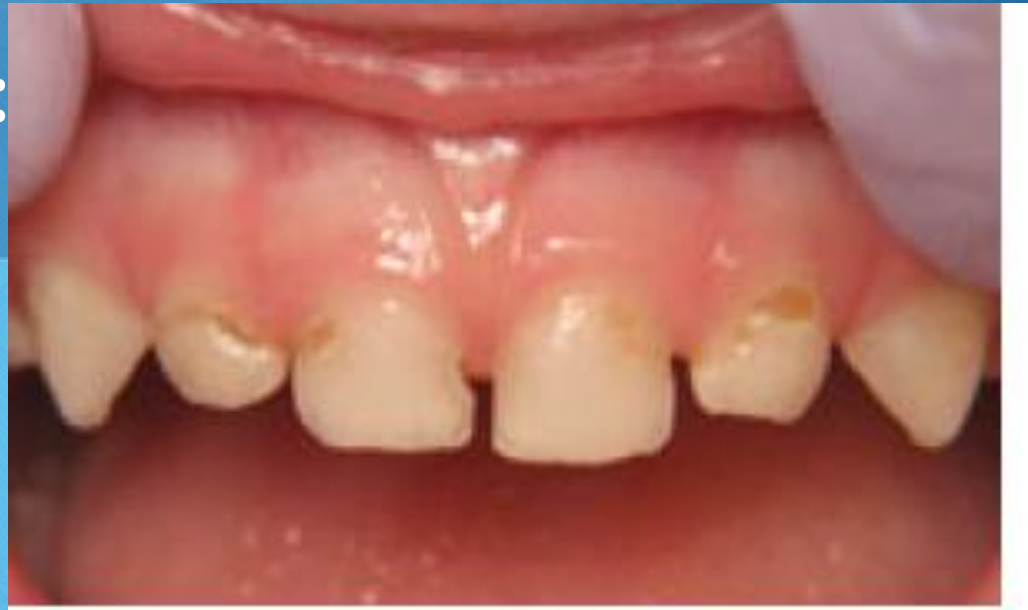

## Question #3

- What is your assessment based on this information? (regarding BMI, and patient behavior)



- The patient warms up to you, and is seated in the chair. You begin your clinical exam, and this is what you see. Please describe your findings.

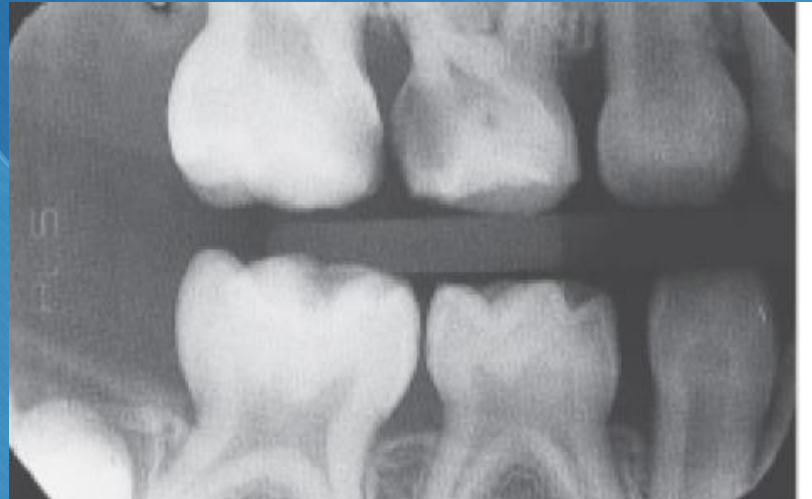



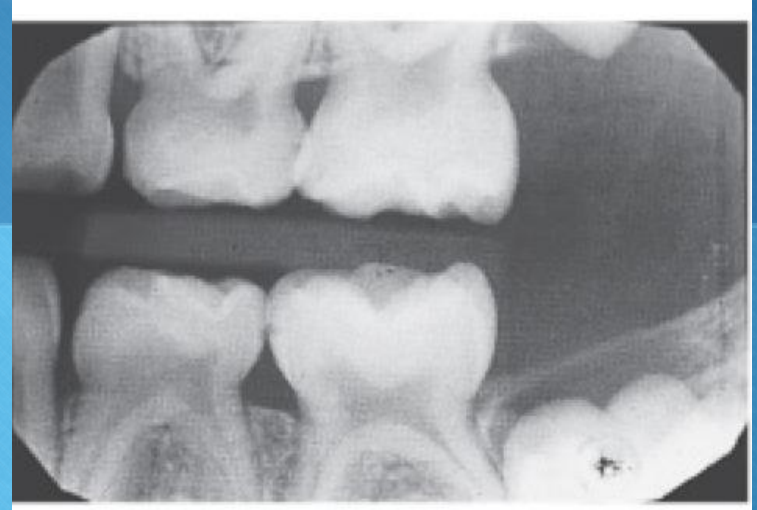
## Question #6

- The patient, now more relaxed, is happily interacting with your lead assistant. She is excited to take x-rays, and uses tell-show-do on the patient. The patient sits on the chair with a lead apron on. Based on his presentation, and your clinical exam, describe how you would proceed with your radiographic exam?





he





# Findings

- #A: MO Caries
- #B: DO Caries
- #D: Mesial, distal and facial caries
- #E: : Mesial, distal and facial caries
- #F: Mesial and distal caries
- #G : Mesial, distal and facial caries
- #K: Occlusal caries
- #S O caries
- #T Occlusal caries





# Group Activity

- Based on the information provided thus far, please utilize the AAPD guidelines (provided) to construct a treatment plan for the management of this patient.